Cryoanalgesia for shoulder pain: a motor-sparing approach to rotator cuff disease

Agnes Reka Stogicza ,[1] Philip Peng [2]

[1]Anesthesia and Pain, Saint Magdolna Private Hospital, Budapest, Hungary
[2]Anesthesia, Toronto Western Hospital, University Health Network, Toronto, Ontario, Canada

Correspondence to
Dr Agnes Reka Stogicza, Anesthesia and Pain, Saint Magdolna Private Hospital, Budapest, 1023 Hungary; stogicza@gmail.com

Received 12 April 2022
Accepted 3 June 2022

ABSTRACT

Introduction Rotator cuff disease is a common cause of musculoskeletal pain and disability, and the management can be challenging. Joint denervation emerges as a new technique, but the literature on shoulder neural ablation procedure is largely limited to pulsed radiofrequency due to the concern of motor impairment. We described a novel motor-sparing approach of cryoablation for the management of shoulder pain based on the recent literature on the innervation of shoulder.

Methods Four patients with a history of rotator cuff disease refractory to conservative therapy and not amenable to surgery underwent a ultrasound-guided cryoablation of the capsular branches of the shoulder joint after a positive diagnostic injection. The target articular branches were based on the anatomical landmarks described in recent publication. They were the acromial, superior and inferior branches of the suprascapular nerve, the anterior branch of the axillary nerve, the nerve to the subscapularis, which were all located around the superior, posterior and anterior glenoid. The lateral pectoral nerve articular branch was targeted at the coracoclavicular space.

Results All four patients experienced at least 60% pain relief with improvement in function for 6–12 months following the procedure without any clinical evidence of motor impairment. No adverse effect was observed.

Discussion Based on the current understanding of the glenohumeral joint articular branches and their relationship to the bony landmark, targeting the articular branches only was feasible and led to good outcomes. Further large prospective cohort study is needed.

INTRODUCTION

Shoulder pain is a common cause of musculoskeletal pain, surpassed only by low back and knee pain,[1] with a prevalence of 8.4 per 100 people over the age of 18.[2] Rotator cuff disease is the most common contributor to shoulder pain, affecting the quality of life and leading to prolonged disability and substantial economic burdens for society.[3 4]

Rotator cuff disease represents a spectrum of pathology: partial tear, tendinopathy, and full thickness tear. The management is divided into non-operative measures and surgery.[3 4] The former includes activity modification, anti-inflammatory agents, physical therapy, and subacromial bursa injection with local anesthetic and steroids. For surgical options, rotator cuff repair or subacromial decompression are considered in patients with or without full-thickness tendon tears.[5] In patient without full-thickness tear, literature suggests that the outcomes are equivalent between the surgical and non-surgical options.[6] Since rotator cuff disease is the most common cause of prolonged shoulder pain and disability, advanced non-surgical treatment may be required. Joint denervation emerges as a new modality of non-surgical treatment of shoulder pain.[7] We reported our experience of managing four consecutive patients with rotator cuff disease using a novel motor-sparing technique of cryoanalgesia based on the recent understanding of the innervation of the shoulder.[8–10]

METHODS

This is a retrospective case report of four patients who underwent cryoanalgesia of the capsular branches of the shoulder at Budapest St. Magdolna Private Hospital. All patients included in our report provided written consent for this report. According to our institution ethic board, no ethic approval is required for this case report.

Patient information

Four patients suffering from recalcitrant shoulder pain secondary to rotator cuff disease, either deemed as non-surgical candidates or refused to have shoulder surgery, were referred to the Budapest St. Magdolna Private Hospital for minimally invasive treatment. They had previously tried pharmacological management, physical therapy, hyaluronidase, and steroid injections without any sustained benefit.

All four patients suffered from advanced rotator cuff disease. The numeric pain score with movement was high, ranging from 7 to 10 (0 is the lowest and 10 the highest possible score) and all suffered from significant functional impairment. The types of pathology and previous treatment are summarized in table 1.

Intervention management

All patient received a diagnostic block. Both the diagnostic injection and the cryoanalgesia procedure were performed after obtaining informed written consent with discussion of potential risks and benefits. The targets for both diagnostic and cryoanalgesia were the same. For diagnostic block, each patient received 0.5 mL lidocaine 1% at each target and all experienced more than 50% symptoms relief for several hours.

Novel motor-sparing approach to shoulder cryoanalgesia: diagnostic block and cryoanalgesia

The targets for the diagnostic block and cryoanalgesia was based on the anatomic description published previously.[8–10] The targets are the acromial, superior and inferior branches of the suprascapular nerve, the anterior branch of axillary nerve,

Check for updates

© American Society of Regional Anesthesia & Pain Medicine 2022. No commercial re-use. See rights and permissions. Published by BMJ.

To cite: Stogicza AR, Peng P. *Reg Anesth Pain Med* Epub ahead of print: [*please include* Day Month Year]. doi:10.1136/rapm-2022-103670

Reg Anesth Pain Med: first published as 10.1136/rapm-2022-103670 on 14 June 2022. Downloaded from http://rapm.bmj.com/ on June 14, 2022 at American Society for Regional Anesthesia (ASRA). Protected by copyright.

Table 1 Demographic and clinical findings

Demographic		Clinical findings and previous relevant treatment	Functional impairment
1	73/F/26	Rotator cuff tear with glenohumeral joint disease, surgery offered but declined Multiple steroid (subacromial and intraarticular) injections received before.	Overhead activity impossible, severe impairment of sleep. Hawkins test* positive.
2	67/F/26	Complete rupture supraspinatus tendon, infraspinatus muscle fatty degeneration, SLAP lesion. Acromioclavicular joint distended with fluid. Intraarticular steroid injection with initial good relief.	Constant shoulder pain with severe decrease ROM and limited overhead activity. Hawkins test positive.
3	65/M/25	Supraspinatus tendinopathy with the long head of biceps injury, advanced glenohumeral joint osteoarthritis with cartilage destruction. Fluid around the long head of biceps. Joint replacement offered and declined	Pain most pronounced in anterior shoulder especially over bicipital groove, ROM very limited due to pain. Hawkins test positive.
4	72/M/27	Supraspinatus tendon rupture, surgery refused. Small amount of fluid around the long head of biceps. Early glenohumeral and acromioclavicular joint arthritis.	Painful and limited overhead activity but ROM otherwise preserved. Hawkins test positive.

Demographic data was displayed with age/sex/body mass index.
SLAP lesion refers to the injury of the superior part of glenoid labrum in the vicinity of the origin of the long head of biceps.
*Hawkins test is a clinical test to assess the presence of shoulder impingement of the rotator cuff.
ROM, range of movement.

the nerve to subscapularis and the lateral pectoral nerve articular branch.

The procedure was performed under strict aseptic technique. Lidocaine 1% was used for infiltration of skin. For diagnostic block, a 22-gage 3.5-inch spinal needle was used. The cryoanalgesia was achieved with a single use cannula (METRUM cryoflex, Warsaw, Poland) with 1.3 mm wide 10 mm active tip. The lesions were performed at −70°C for 90 s two times, followed by a 30 s defrost cycle. No medication was injected afterward.

Acromial and superior branches of the suprascapular nerve

The first part of the procedure targeted the acromial and superior branches of the suprascapular nerve in the supraspinatus fossa. The patient was placed in the lateral decubitus position with the target shoulder as the non-dependent side. A curvilinear probe (2–6 MHz) was placed over the supraspinatus fossa tilting in the medial direction (figure 1A). Sliding the probe anteriorly allowed the identification of the scapular notch, which had a unique echographic appearance (figure 1A). The target for the acromial branch of the suprascapular nerve was the glenoid just lateral to the notch. The cryoanalgesia probe was inserted in-plane in a medial-to-lateral direction under ultrasound guidance. Once the probe contacted bone, the cryoanalgesia was initiated.

The same skin entry was used for the superior branch of the suprascapular nerve, with the cryoprobe-redirected posteriorly to visualize the posterosuperior glenoid, which was an easily identifiable target (figure 1A). Cryoablation was performed again, as above described.

Inferior branch of the suprascapular nerve

The targets for the inferior branch of the suprascapular nerve were the superior and inferior aspect of the posterior glenoid. The curvilinear probe was initially placed parallel and caudal to the scapular spine in the infraspinatus fossa. At this position, the superoposterior glenoid could be seen lateral to the spinoglenoid notch (figure 1B). The cryoanalgesia probe was inserted in-plane in a medial-to-lateral direction towards the superoposterior glenoid. By moving the ultrasound probe in the caudal direction, the inferoposterior glenoid, characterized by the flat surface of the posterior scapular blade on the medial side, became the second target for cryoanalgesia (figure 1B).

Nerve to the subscapularis and anterior branch of the Axillary Nerve

This part of the procedure was performed with the patient in supine position. The upper and lower half of the anterior glenoid were the targets for the nerve to subscapularis and the anterior articular branch of axillary nerve, respectively (figure 2A). Ultrasound identification of the glenoid here was more challenging and highly dependent on the position of the scapula and the body habitus of the patient. Curvilinear ultrasound was used for the location of the axillary artery and brachial plexus for safety purpose and the cryoprobe was inserted in an out-of-plane approach to the glenoid (figure 2D). We used a combined fluoroscopy/ultrasound technique. We recommended using fluoroscopy for confirmation of needle position or as sole procedure for patient with high body mass index.

With fluoroscopy, an posteroanterior view was obtained to allow visualization of the anterior glenoid. Following local anesthesia infiltration of the skin, the cryoprobe was placed in a coaxial view to the upper part of the glenoid until bony contact was achieved (figure 2E). To ensure that the brachial plexus was not at risk, motor stimulation was performed through the cryoprobe at 2 Hz up to 2V to make sure the absence of muscle contraction in the upper extremity. Cryoablation was then performed. From the same skin entry, the cryoanalgesia probe was redirected in caudad direction to reach the lower portion of the anterior glenoid, targeting the anterior branches of the axillary nerve. Motor stimulation followed by lesioning was performed in a similar manner.

Lateral pectoral Nerve

This part of the procedure was performed with the patient remaining in supine position. The lateral pectoral nerve runs together with the acromial branch of the thoracoacromial artery, which is a superficial target easily identified with a linear probe (6–15 MHz) between the coracoid process and the clavicle (figure 2A–C). The cryoanalgesia cannula was inserted in-plane in a caudal-to-cephalad direction over the coracoid process in the vicinity of the artery. Figure 2C demonstrated the presence of the 'ice ball' just over the lateral pectoral nerve on the coracoid process.

RESULTS

Four patients, two women and two men between 65 and 73 years old, received the novel procedures (table 1). All subjects had physical findings and ultrasound assessment confirming the presence of rotator cuff disease with varied degrees of glenohumeral osteoarthritis. All patients underwent motor-sparing shoulder denervation of multiple articular branches. They all experienced at least 60% pain relief and an improvement in shoulder function and sleep at the 3-month assessment. The

Reg Anesth Pain Med: first published as 10.1136/rapm-2022-103670 on 14 June 2022. Downloaded from http://rapm.bmj.com/ on June 14, 2022 at American Society for Regional Anesthesia (ASRA). Protected by copyright.

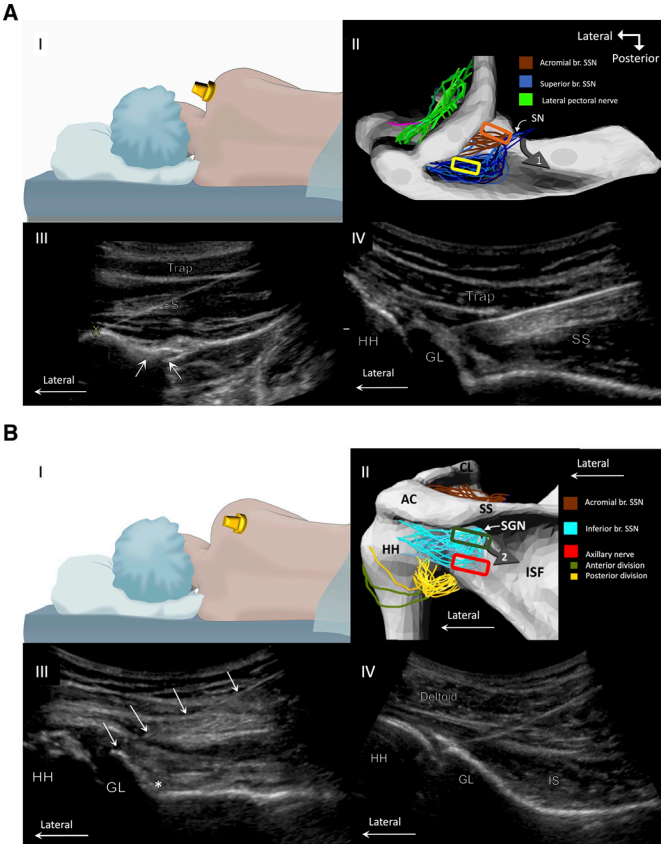

Figure 1 Targets for suprascapular nerve at supraspinatus and infraspinatus fossa. (A) At the supraspinatus fossa. I. The position of the patient and the curvilinear probe in the supraspinatus fossa. II. The distribution of articular branches of the suprascapular nerve (SSN) in superior scapula adapted from Tran *et al*.[8] The positions of the ultrasound probe are also shown here. The orange and yellow rectangles represented the position where the ultrasound images in III and IV were taken, respectively. Gray arrow indicates the course of the motor branch to the supraspinatus. III. Ultrasound image at scapular notch. The target for acromial branch is marked with X and the notch is marked with arrows. IV. Ultrasound image at the suprascapular fossa. The target of the superior branch of the suprascapular nerve is the anterosuperior glenoid. (B) At the infraspinatus fossa. I. The position of the patient and the curvilinear probe in the infraspinatus fossa. II. The distribution of articular branches to the shoulder in posterior scapula adapted from Tran *et al*.[8] The positions of ultrasound probe are also shown here. The green and red rectangles represented the position where the ultrasound images in III and IV were taken, respectively. The gray arrow indicates the motor branch to the infraspinatus. III. Ultrasound image at superoposterior glenoid. At this position, the spinoglenoid notch (*) is seen on the medial aspect of the GL. The needle is indicated by the arrows. IV. Ultrasound image at the inferoposterior glenoid. At this site, the scapula on the medial aspect of the glenoid is smooth. GL, glenoid; HH, humeral head; IS, infraspinatus; SS, supraspinatus; Trap, trapezius; SN, scapular notch. Reproduced with courtesy of Philip Peng Educational Series and Dr. Agnes Stogicza.

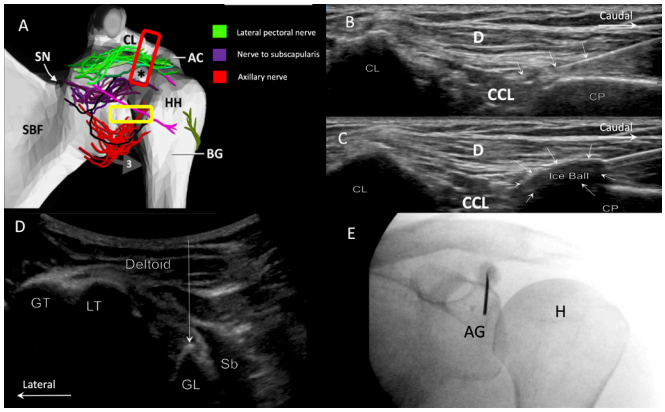

Figure 2 Targets in anterior scapula. (A) The distribution of articular branches of the shoulder in the anterior scapula adapted from Tran *et al*.[8] The positions of ultrasound probe are also shown here. The red and yellow rectangles represented the positions where the ultrasound images in (B) and (D) were taken respectively. (B). Ultrasound image between the clavicle (CL) and coracoid process (CP). At this position, the lateral pectoral nerve is superior to the CP in the fascia layer sandwiched between the deltoid (D) and the coracoclavicular ligament (CCL). The needle was indicated by arrows. (C) Ultrasound image showing the 'ice ball' created by the cryoprobe. (D) Ultrasound image at the anterior glenoid (GL). The needle trajectory is indicated by the arrow. GT, greater tuberosity; LT, lesser tuberosity; SB, subscapularis. (E) Fluoroscopic image of anterior glenoid (AG) and the needle position. H, humeral head. Reproduced with courtesy of Philip Peng Educational Series and Dr. Agnes Stogicza.

analgesic benefit sustained for patient 1, 2 and 4 at the 6-month assessment. At 12-month assessment, the pain relief of patient 1 and 2 sustained while patient 4 was assessed up to 6 months following the cryoanaglesia procedure at the time of writing. The pain intensity of patient 3, who had the most advanced disease in the glenohumeral joint, returned to baseline level at 6 months (figure 3). Patient 1 expressed significant improvement in the movement of the shoulder and patient 2 reported shoulder pain no longer a limitation at all to her daily activity. There were no procedural complications. Although all patients reported post procedural discomfort for 2–3 days, all responded to minor analgesics. In addition, no supraspinatus or infraspinatus weakness was clinically evident in any of the patients.

DISCUSSION

Joint denervation is an emerging technique for managing pain in the large joints.[11 12] For the shoulder joint, the literature focused on the radiofrequency procedures.[7] Interestingly, most investigators chose the suprascapular nerve as sole target and adopted pulsed rather than the thermal ablation as the principal technique to avoid the loss of motor function.[7] With the current understanding of the shoulder innervation and the pertinent bony landmarks,[8–10] this report described a novel motor-sparing cryoanalgesia technique aiming at the small articular branches of the suprascapular, lateral pectoral, subscapularis and the anterior branch of axillary nerves. This concept was inspired by the pericapsular approach to multiple articular branches in knee and hip.[12 13]

The shoulder joint and surrounding tissues (rotator cuff and ligaments) are innervated principally by four nerves: suprascapular, lateral pectoral, axillary and subscapular nerves (figure 4).[8–10] For rotator cuff disease, the relevant structures in superior and anterior shoulder are innervated by the suprascapular, lateral pectoral, subscapular, and anterior branch of axillary nerves. These structures in the superior and anterior shoulder are richly innervated by the nociceptive fibers.[9] Therefore, we targeted these nerves in our current case reports.

Since the suprascapular nerve is a mixed motor and sensory nerve, denervation of the nerve trunk at the floor of the supraspinatus fossa will lead to motor function loss.[14] Recent anatomy

Reg Anesth Pain Med: first published as 10.1136/rapm-2022-103670 on 14 June 2022. Downloaded from http://rapm.bmj.com/ on June 14, 2022 at American Society for Regional Anesthesia (ASRA). Protected by copyright.

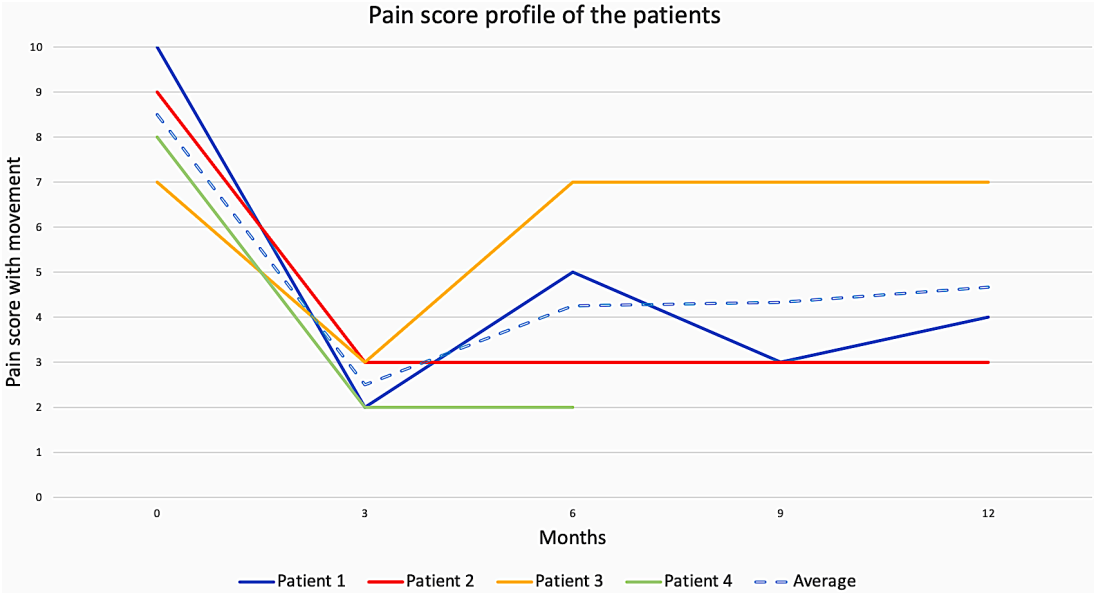

Figure 3 Numeric pain scores profile.

literature allows us to develop new target to the articular branches only. The acromial branch, the first branch of the suprascapular nerve, can be targeted at the anterosuperior glenoid lateral to the scapular notch and has been validated.[15] After giving out the acromial branch, the suprascapular nerve bifurcates into medial and lateral trunks deep to the supraspinatus. The medial trunk provides motor branches to the supraspinatus, whereas the lateral trunk courses along the floor of the supraspinous fossa to reach the spinoglenoid notch. Along its course, the lateral trunk gives off articular branch (superior branch) and can be targeted at the posterosuperior glenoid. The lateral trunk of suprascapular nerve continues inferiorly to enter the infraspinous fossa and provides motor fibers to the infraspinatus. It also gives the inferior branch that courses laterally to the posterosuperior glenohumeral joint capsule located deep to the tendon of the infraspinatus. The target of the inferior branch is the posterior glenoid, which is easily visualized with ultrasound. Therefore, all the targets for the suprascapular nerve denervation are directed to the articular branches in the pericapsular area (figure 4).

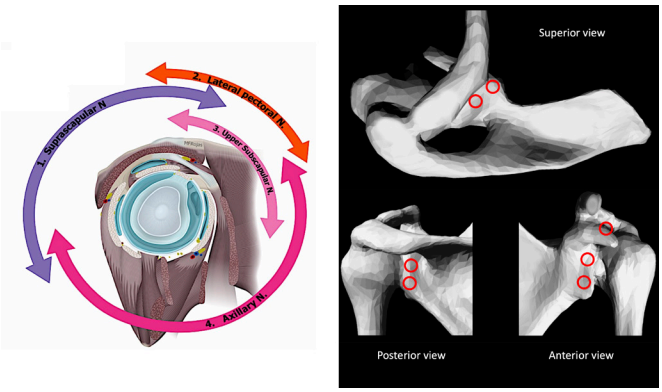

Figure 4 Left: a schematic diagram to show the pericapsular coverage of the different nerves to the shoulder. There are overlap in the areas of coverage between different nerves. Right: the targets for the cryoanalgesia in this report are summarized and depicted with red circles. All the targets aim at the articular branches in a pericapsular manner. The left figure was reproduced with the courtesy of Dr. Maria Fernanda Rojas. The right figure was reproduced with courtesy of Philip Peng Educational Series.

The lateral pectoral nerve supplies the pectoral muscles, but the target in our case report is the acromial branch coursing along the superior surface of the coracoid process. It supplies acromioclavicular joint, coracoclavicular and coracoacromial ligaments as well as the subacromial bursa, which are all highly innervated by nociceptive fibers. The landmarks and the details of the anatomy of the lateral pectoral nerve have been described by Tran and colleagues.[15] This nerve was also the target of denervation for patients with shoulder pain in a case series.[16]

The nerve to subscapularis gives off articular branch over the anterior glenoid deep to the subscapularis to innervate the subcoracoid bursa and the anterosuperior glenohumeral joint. The axillary nerve, after leaving the posterior cord, courses in an inferolateral direction along the surface of the subscapularis to reach the inferior border and continues through the quadrangular space. It sends articular branch superiorly deep to the tendon of the subscapularis and supply the anteroinferior glenohumeral joint. Therefore, the anterior glenoid deep to the subscapularis (deep subscapular plane) is the target for denervation of both the anterior branch of axillary nerve and the nerve to subscapularis.[17]

Cryoanalgesia technique was used in this case report. It was based on the anecdotal experience of the authors who found better results compared with that from the radiofrequency ablation with conventional needle. At this time, it was unclear that the 'ice ball' created by the cryo-probe allowed a better capture of the articular branches but the first 4 patients received this technique received great and prolonged analgesic effect. With the technique described in our patients, the needle trajectory was at a steep angle to the bone surface where the articular branches course. This would decrease the lesion capturing at the bone surface should radiofrequency ablation be used.[18] With the increase in size of lesion (quite common to see the lesion size in the range of 13×10 mm in the ultrasound image), it offsets the decrease of articular branch capturing due to the steep angle. In addition, the risk of postprocedure neuritis is much lower in cryoanalgesia, and the effect is much more evident in the early postprocedure

Reg Anesth Pain Med: first published as 10.1136/rapm-2022-103670 on 14 June 2022. Downloaded from http://rapm.bmj.com/ on June 14, 2022 at American Society for Regional Anesthesia (ASRA). Protected by copyright.

period. Patient 3 had the most severe concomitant glenohumeral joint arthritis, which may account for the suboptimal result because the articular branch from the posterior branch of the axillary nerve was spared.

In summary, chronic shoulder pain related to the rotator cuff disease can be difficult to manage. Joint denervation emerges as a new technique, but the literature on shoulder denervation procedures is largely limited to the pulsed radiofrequency due to the concern of motor impairment. Current understanding of the articular branches and their relationship to the bony landmark allows practitioners to investigate the optimal motor-sparing targets for ablation. The rotator cuff and the surrounding structures are innervated by the articular branches from the suprascapular, lateral pectoral, axillary, and subscapular nerves. We presented a novel technique in which we targeted at the four nerves at various pericapsular points (figure 4) with good analgesia effects. While case report typically is limited by the small sample size and tends to overestimate the therapeutic effect, the anatomic basis of the lesion in this case series stimulates the thinking of a new approach for the ablation technique for patients with chronic shoulder pain due to rotator cuff disease. Further prospective large case cohort study is needed.

Twitter Agnes Reka Stogicza @StogiczaAgnes and Philip Peng @DrPhilipPeng

Acknowledgements Communication with Thiago Nouer MD, CIPS inspired this technique beyond the available literature.

Contributors Both authors contributed to the preparation of the manuscript.

Funding PP received equipment support from Sonosite Fujifilm Canada.

Competing interests None declared.

Patient consent for publication Not applicable.

Ethics approval This study involves human participants but NA exempted this study. Participants gave informed consent to participate in the study before taking part.

Provenance and peer review Not commissioned; externally peer reviewed.

ORCID iDs
Agnes Reka Stogicza http://orcid.org/0000-0001-8045-9185
Philip Peng http://orcid.org/0000-0003-1704-7991

REFERENCES

1 Urwin M, Symmons D, Allison T, *et al*. Estimating the burden of musculoskeletal disorders in the community: the comparative prevalence of symptoms at different anatomical sites, and the relation to social deprivation. *Ann Rheum Dis* 1998;57:649–55.
2 Cadogan A, Laslett M, Hing WA, *et al*. A prospective study of shoulder pain in primary care: prevalence of imaged pathology and response to guided diagnostic blocks. *BMC Musculoskelet Disord* 2011;12:119.
3 Oh LS, Wolf BR, Hall MP, *et al*. Indications for rotator cuff repair: a systematic review. *Clin Orthop Relat Res* 2007;455:52–63.
4 Hsu J, Keener JD. Natural history of rotator cuff disease and implications on management. *Oper Tech Orthop* 2015;25:2–9.
5 Jancuska J, Matthews J, Miller T, *et al*. A systematic summary of systematic reviews on the topic of the rotator cuff. *Orthop J Sports Med* 2018;6:232596711879789.
6 Cederqvist S, Flinkkilä T, Sormaala M, *et al*. Non-Surgical and surgical treatments for rotator cuff disease: a pragmatic randomised clinical trial with 2-year follow-up after initial rehabilitation. *Ann Rheum Dis* 2021;80:796–802.
7 Pushparaj H, Hoydonckx Y, Mittal N, *et al*. A systematic review and meta-analysis of radiofrequency procedures on innervation to the shoulder joint for relieving chronic pain. *Eur J Pain* 2021;25:986–1011.
8 Tran J, Peng PWH, Agur AMR. Anatomical study of the innervation of glenohumeral and acromioclavicular joint capsules: implications for image-guided intervention. *Reg Anesth Pain Med* 2019;44:452–8.
9 Laumonerie P, Dalmas Y, Tibbo ME, *et al*. Sensory innervation of the human shoulder joint: the three bridges to break. *J Shoulder Elbow Surg* 2020;29:e499–507.
10 Eckmann MS, Bickelhaupt B, Fehl J, *et al*. Cadaveric study of the articular branches of the shoulder joint. *Reg Anesth Pain Med* 2017;42:564–70.
11 Kumar P, Hoydonckx Y, Bhatia A. A review of current denervation techniques for chronic hip pain: anatomical and technical considerations. *Curr Pain Headache Rep* 2019;23:38.
12 McCormick ZL, Cohen SP, Walega DR, *et al*. Technical considerations for genicular nerve radiofrequency ablation: optimizing outcomes. *Reg Anesth Pain Med* 2021;46:518–23.
13 Girón-Arango L, Peng PWH, Chin KJ, *et al*. Pericapsular nerve group (PENG) block for hip fracture. *Reg Anesth Pain Med* 2018;43:1–63.
14 Tran J, Peng P, Agur A. Evaluation of suprascapular nerve radiofrequency ablation protocols: 3D cadaveric needle placement study. *Reg Anesth Pain Med* 2019;44:1021–5.
15 Tran J, Peng P, Agur A, *et al*. Diagnostic block and radiofrequency ablation of the acromial branches of the lateral pectoral and suprascapular nerves for shoulder pain: a 3D cadaveric study. *Reg Anesth Pain Med* 2021;46:305–12.
16 Eckmann MS, Lai BK, Uribe MA, *et al*. Thermal radiofrequency ablation of the articular branch of the lateral pectoral nerve: a case report and novel technique. *A A Pract* 2019;13:415–9.
17 Tran J, Agur A, Peng P. Deep plane to subscapularis approach for anterior shoulder analgesia: a tribute to DR Darcy price. *Reg Anesth Pain Med* 2019;44:759–60.
18 Finlayson RJ, Thonnagith A, Elgueta MF, *et al*. Ultrasound-Guided cervical medial branch radiofrequency neurotomy: can Multitined deployment cannulae be the solution? *Reg Anesth Pain Med* 2017;42:45–51.

Reg Anesth Pain Med: first published as 10.1136/rapm-2022-103670 on 14 June 2022. Downloaded from http://rapm.bmj.com/ on June 14, 2022 at American Society for Regional Anesthesia (ASRA). Protected by copyright.